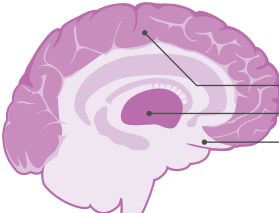



FREQUENZBÄNDER IM EEG

Delta-Wellen



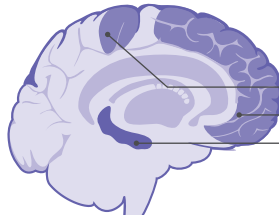
Kortex
Thalamus
suprachiasmatischer Kern



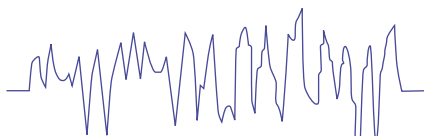
normal:
Tiefschlaf

pathologisch:
Hirnläsion,
Epilepsie

Theta-Wellen



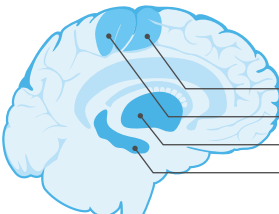
sensorischer Kortex
präfrontaler Kortex
Hippocampus



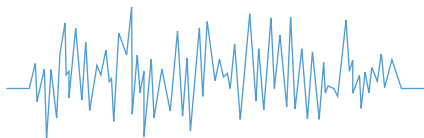
normal:
Schläfrigkeit

pathologisch:
Unaufmerksamkeit,
Tagträumen,
Angst,
ADHS

Alpha-Wellen



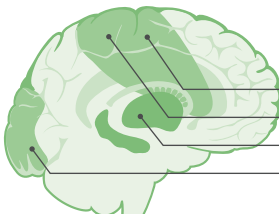
motorischer Kortex
sensorischer Kortex
Thalamus
Hippocampus



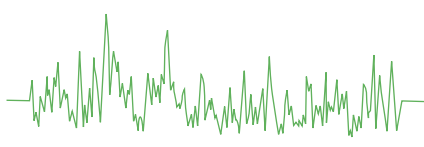
normal:
Entspannung,
Meditation

pathologisch:
Depression,
ADHS

SMR-Wellen

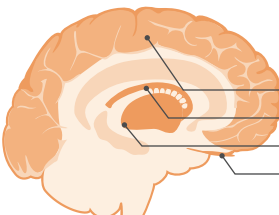


motorischer Kortex
sensorischer Kortex
Hörfelder
Sehfelder

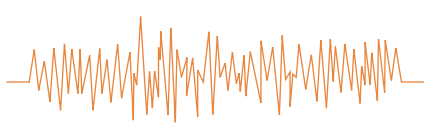


normal:
motorisch ruhig,
geistig konzentriert

Beta-Wellen



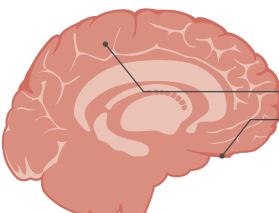
Kortex
Basalganglien
Luys-Körper
Riechkolben



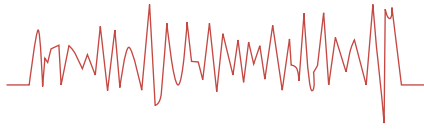
normal:
Konzentration,
Aktivität

pathologisch:
Zwang,
Schlafstörung

Gamma-Wellen



Alle Gehirnstrukturen
Riechkolben



normal:
neuronale Verknüpfung,
Bewusstsein,
komplexe Gedanken

